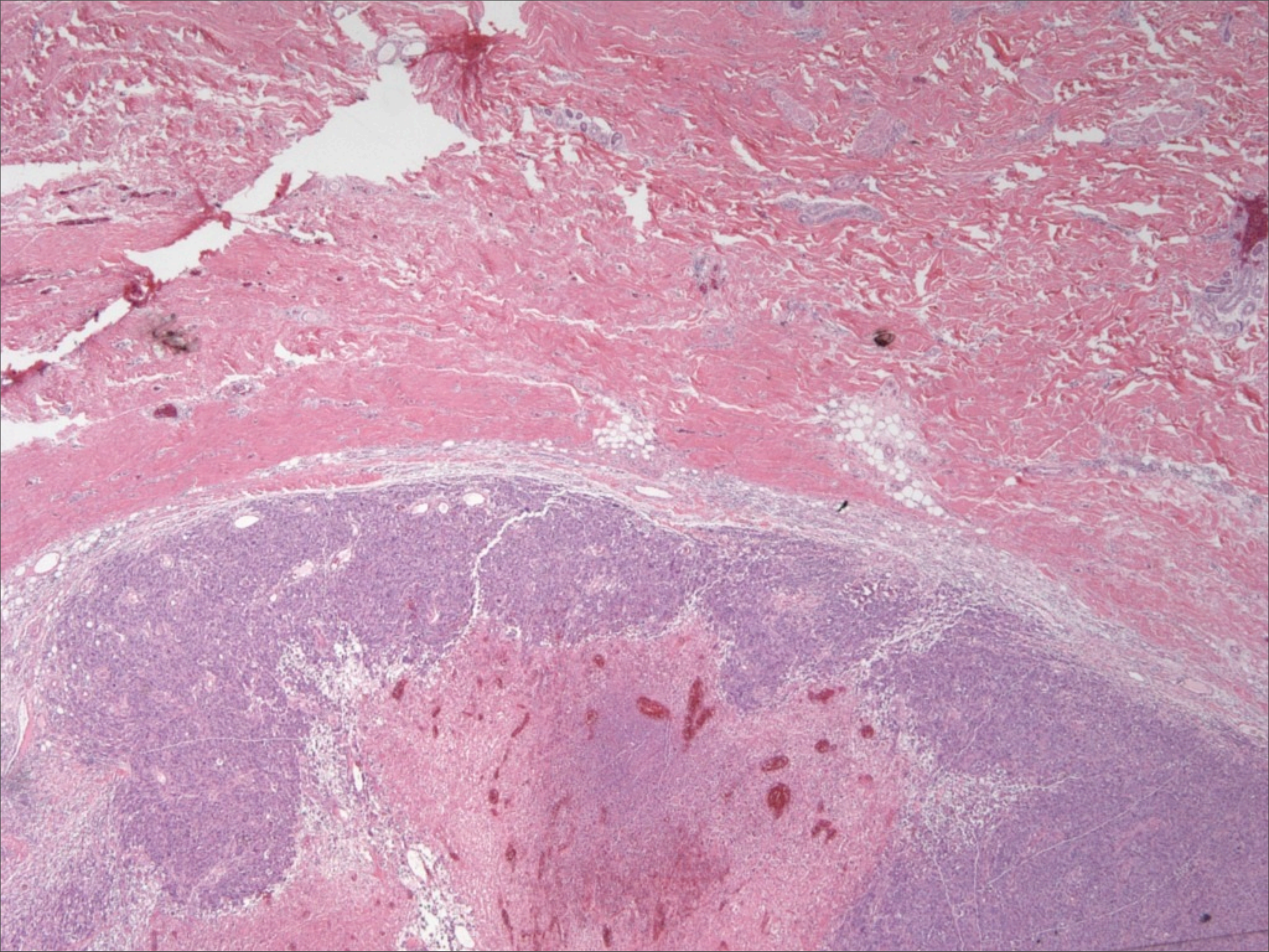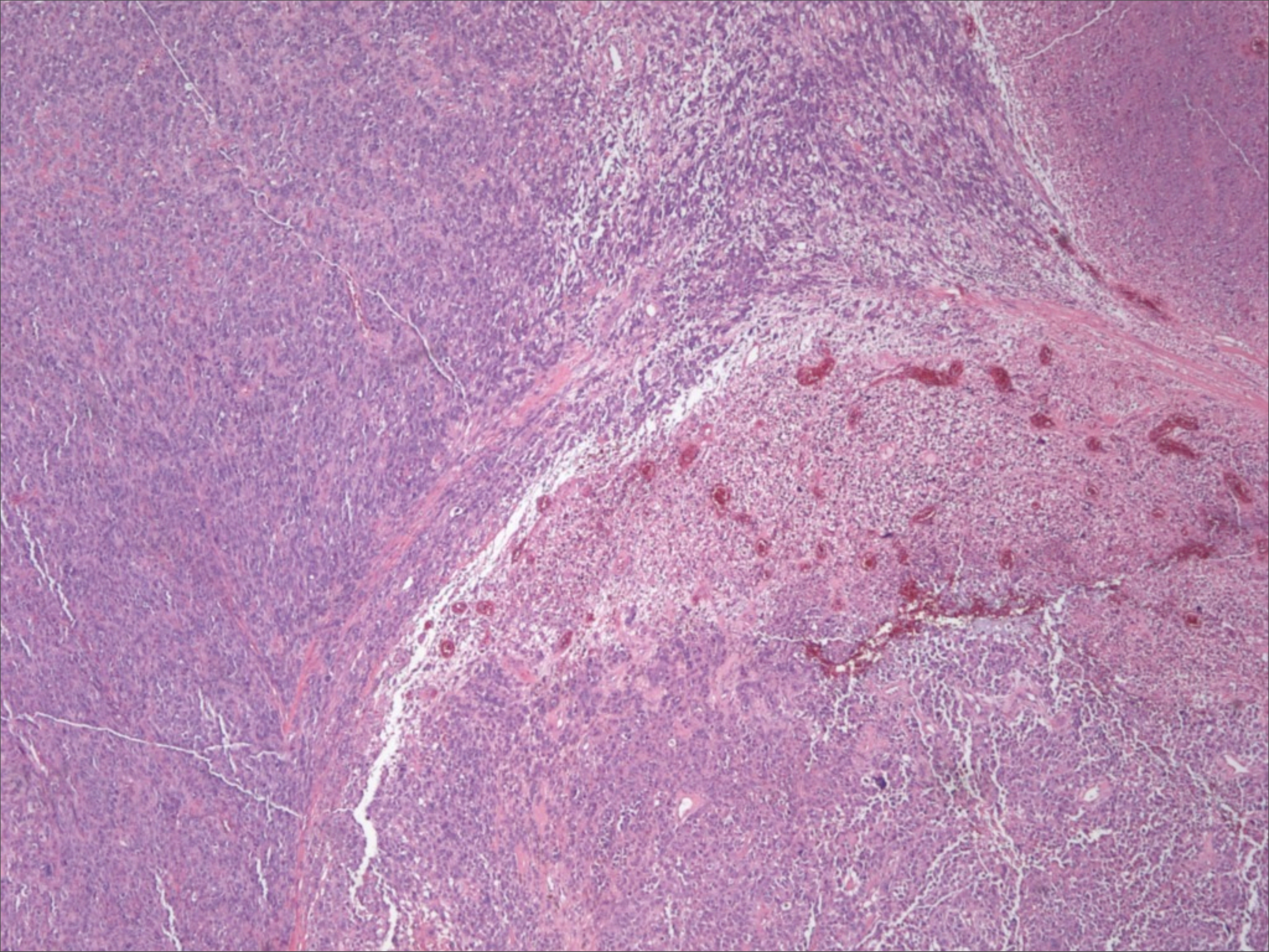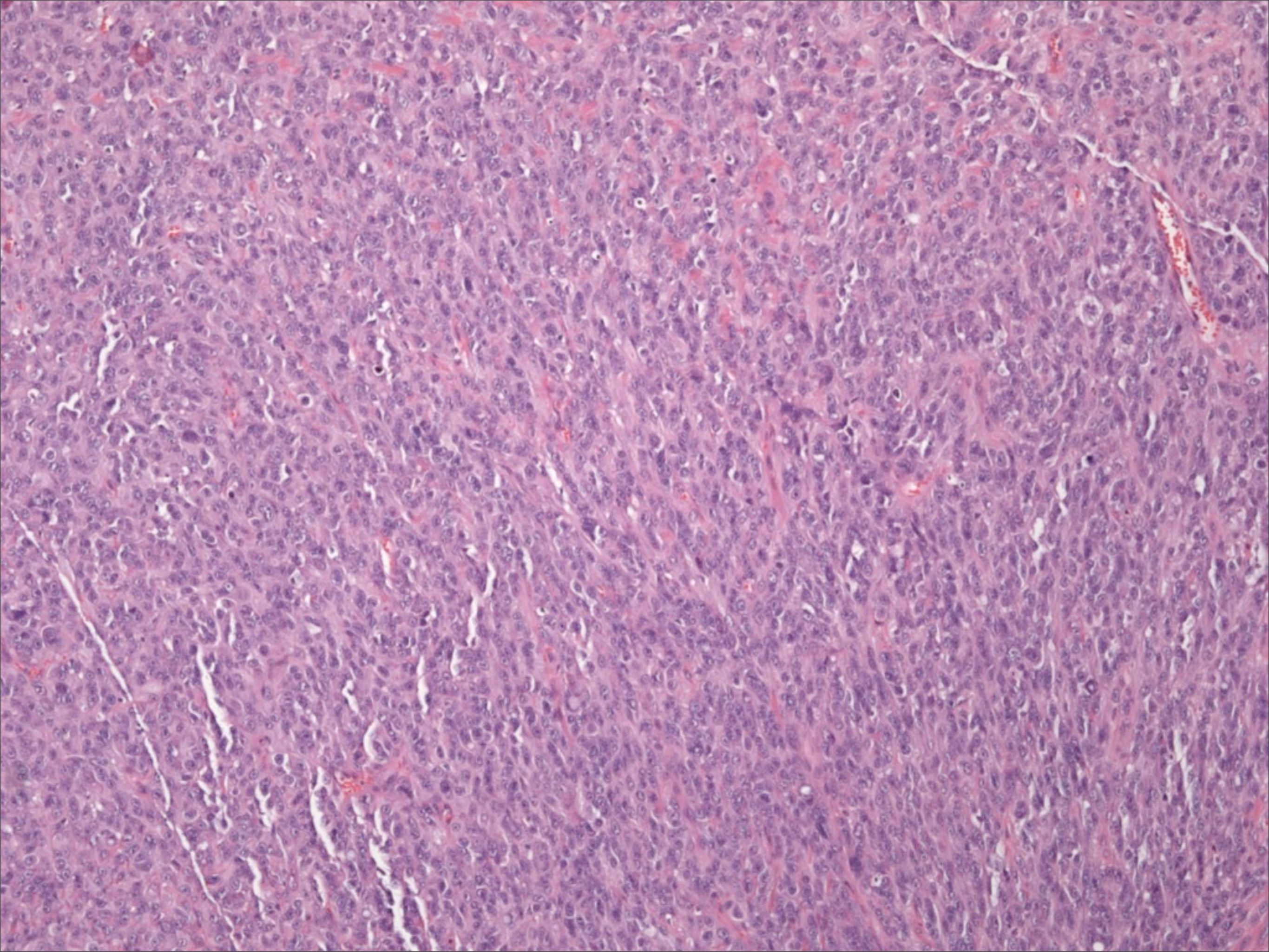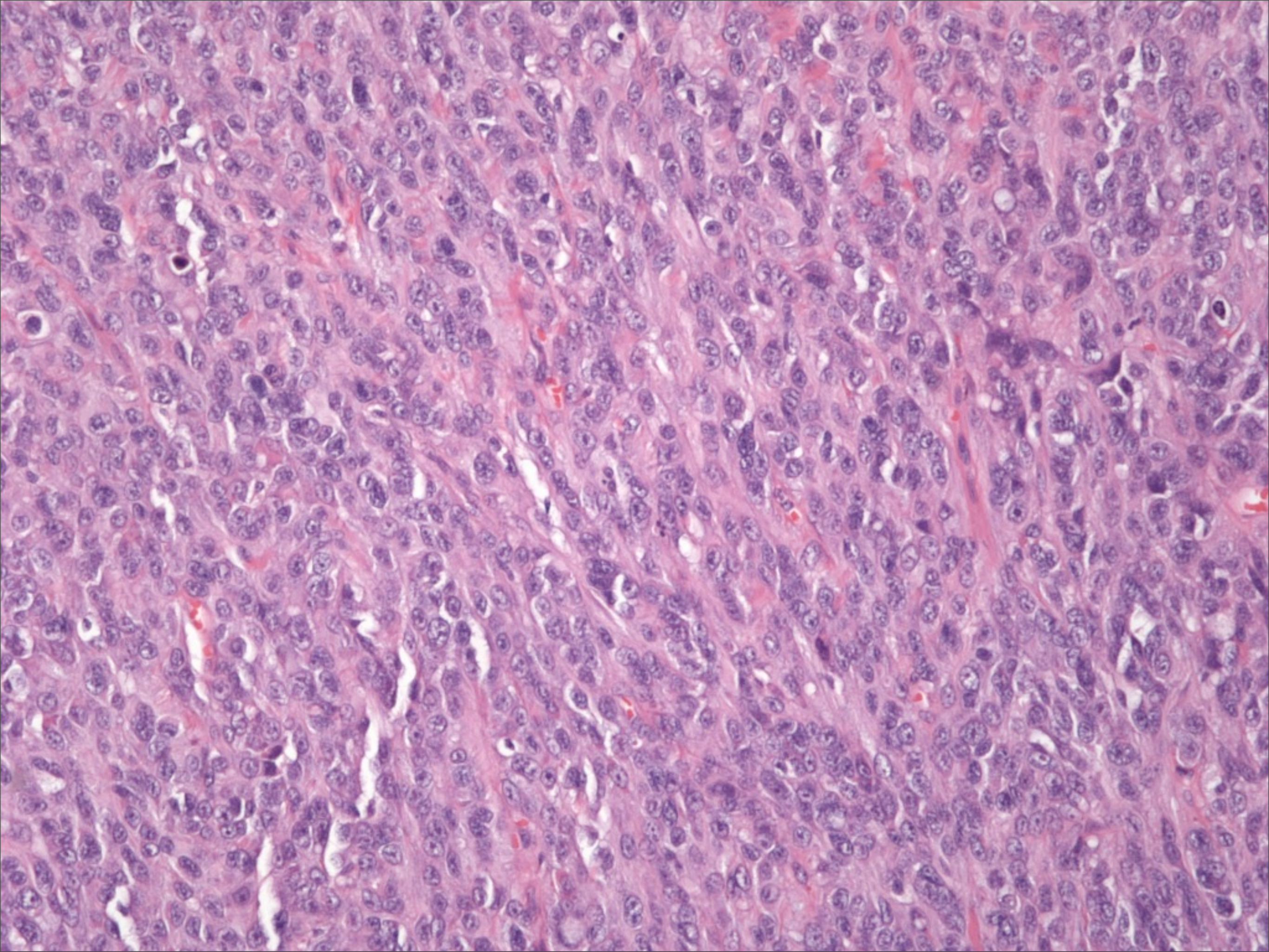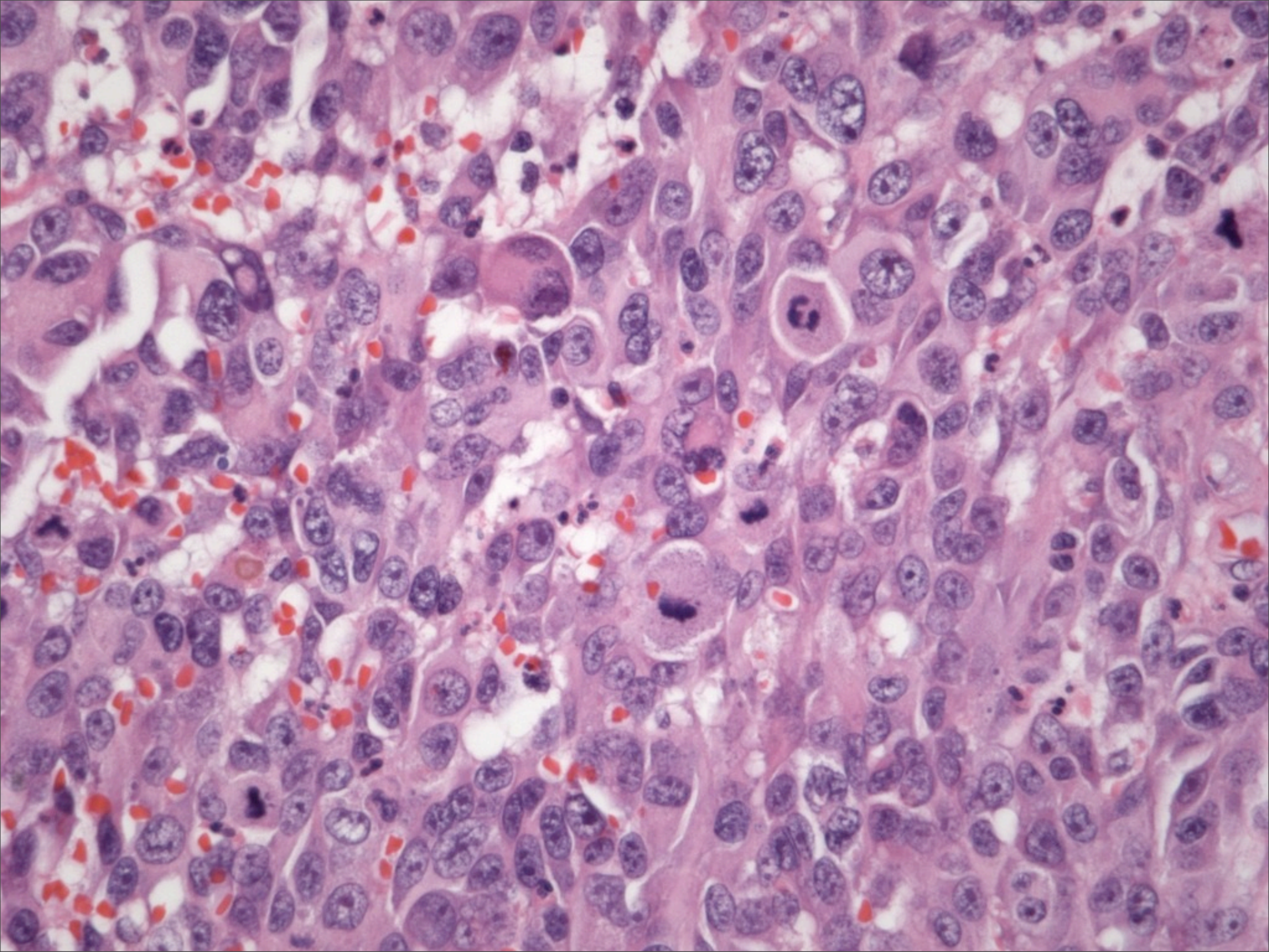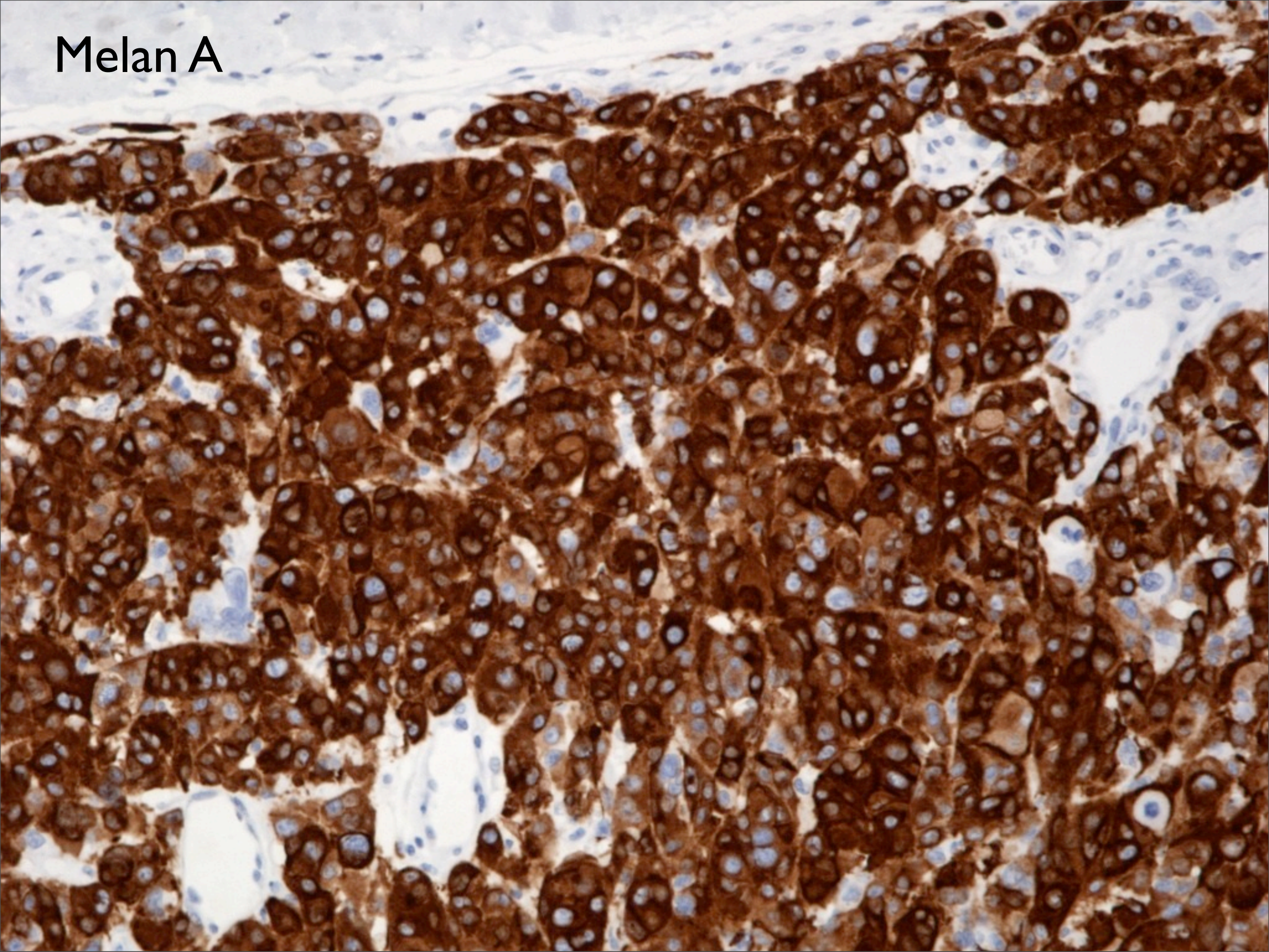
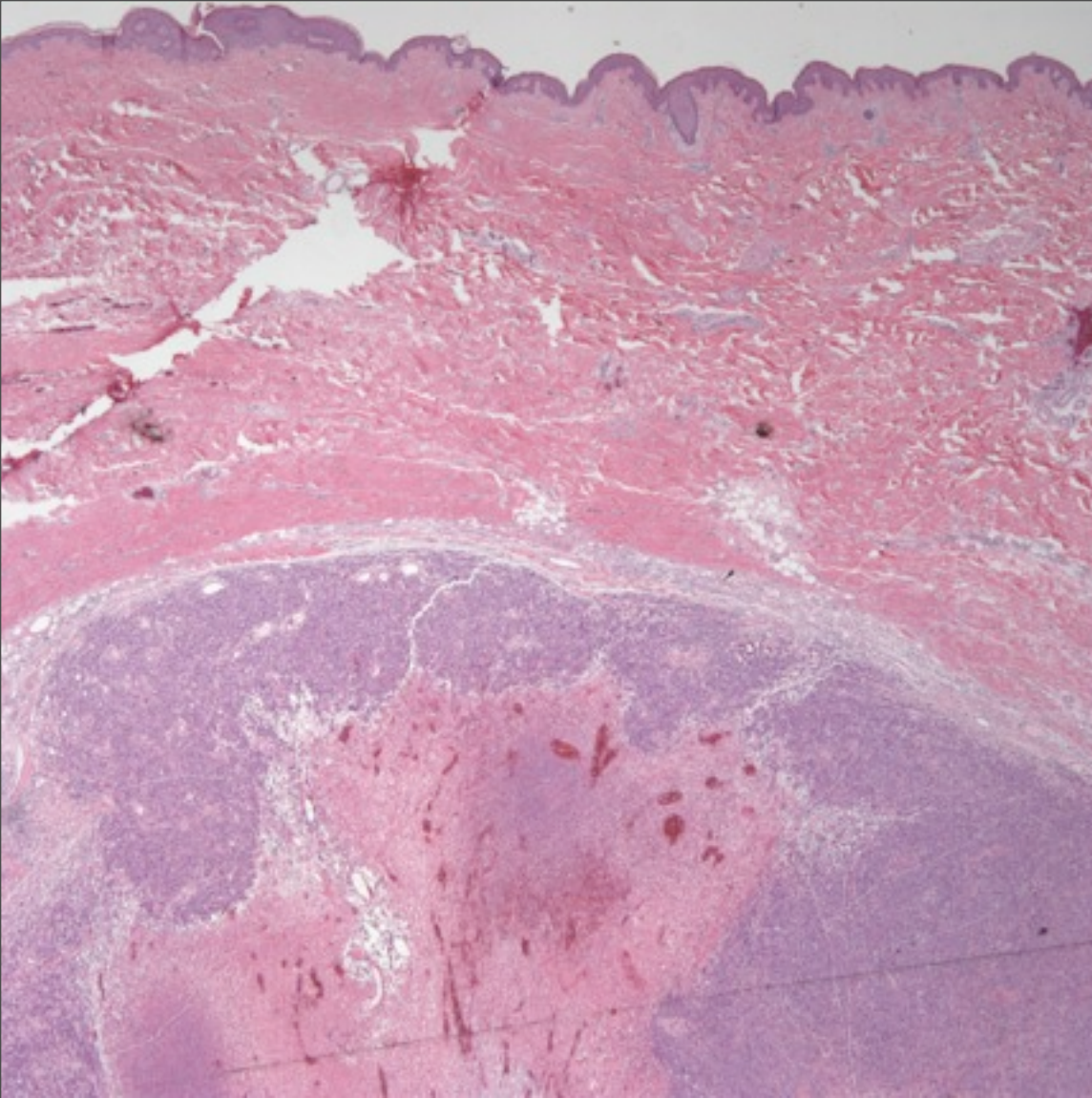


Melan A



Metastatic Amelanotic Melanoma



Dermal location with no
junctional changes

Lymphovascular invasion common

Pleomorphic cells lacking
melanin pigmentation

Confirm with IHC

DDX: Metastatic CA,
lymphoma, sarcoma

